

A NEW DIMENSION IN DIAGNOSTICS, PLANNING AND TREATMENT

3D IMAGING WITH GALILEOS



CONTENTS

EDITORIAL	03
3D X-RAY FOLLOWING IMPLANT COMPLICATIONS	04
3D IMAGE IDENTIFIES ODONTOMA	06
EXACT DETERMINATION OF THE POSITION: BASIS FOR MINIMALLY INVASIVE ORTHODONTIC EXPOSURE	08
DVT FACILITATES THE DIAGNOSIS OF CHRONIC RHINORRHEA AND POSTNASAL SECRETION	09
IMPLANT PLANNING INTEGRATES CAD/CAM AND DVT	11
SAFETY FIRST FOR IMPLANTOLOGY	13
3D DIAGNOSTICS FOR A COMPUTER-AIDED IMPLANT PLAN WITH EXTERNAL SINUS LIFT	15
BENEFITS OF INTEGRATED IMPLANT IN AT RISK PATIENTS	17
CMD DIAGNOSIS AND THERAPY IN ONE APPOINTMENT	19
INTEGRATED FACESCAN SUPPORTS DIAGNOSIS AND SURGICAL PLANNING	20
TODAY'S INTEGRATED SOLUTIONS GIVE US A TASTE OF TOMORROW'S INNOVATIVE THERAPIES	22
LEGAL NOTICE	23

DEAR READERS,



The importance of 3D diagnostics has increased significantly in recent years. A growing number of dentists with different specializations are discovering the advantages of digital volume tomography (DVT) for diagnostics, and are aware of the numerous innovative options it presents for the planning and performing of treatments. As a result, new applications are continuously being developed for oral and maxillofacial surgery, orthodontics, implantology and the analysis of respiratory tract organs. By means of brief case studies, this brochure provides detailed information on the diverse applications of GALILEOS - the high-end digital imaging system from Sirona.

Like all 3D X-ray units from Sirona, GALILEOS stands for the best possible image quality at the lowest dose – and a perfect workflow. The careful coordination of all imaging elements and the loss-free interaction of resolution, noise suppression and filters for reducing metal artifacts, for example, are essential for achieving an excellent image quality. Users are also ensured maximum flexibility with regard to the use of image data: all of the treatment relevant X-ray images can be generated from a single scan.

With the aid of findings-oriented software, GALILEOS offers users enhanced safety and reliability for difficult diagnoses as well as time-saving and efficient workflows. In combination with a surface scan from the optionally integrated FaceSCAN, the DVT also improves patient communication: patients have a better understanding of the diagnoses and opt for the proposed treatment more quickly and more frequently. Patients should also have the smallest possible exposure to radiation. This is why Sirona uses a state-of-the-art image intensifier for large scan volumes. GALILEOS satisfies even the most rigorous standards of general practices, specialists and clinics.

Please enjoy reading,

A handwritten signature in black ink, appearing to read 'Jörg Haist'. The signature is written in a cursive style.

Jörg Haist
Head of Product Management
Imaging systems

3D X-RAY FOLLOWING IMPLANT COMPLICATIONS

AUTHOR Dr. Christian Scheifele, Hamburg (Germany)

When complications arise despite a problem-free intervention, conventional imaging processes are often not able to supply enough information. Cases like this illustrate the added value of 3D X-rays.

With GALILEOS, one scan is enough to capture the patient's entire jaw. As the system moves around the patient, the X-ray volume created provides dentists with all the relevant information they need. All anatomical structures can be analyzed in layers from virtually every perspective. The main advantage of the 3D X-ray scan is its exceptional informative value. A diagnosis can often be established for findings which conventional imaging techniques would not detect. Dentists receive a complete and comprehensive image of the jaw situation. This increases diagnostic accuracy and allows various oral and maxillofacial, orthodontic, ENT and implantology treatments (as illustrated by a specific patient case) to be planned exactly.

A 66-year-old female patient who had suffered tooth loss in region 16 was treated with an implant following an internal sinus lift. Roughly six months later, after an initial symptom-free period, the patient reported recurrent infections and a white discharge from the nose. The post-operative OPT was normal (Fig. 1). Due to persistent peri-implantitis, the implant

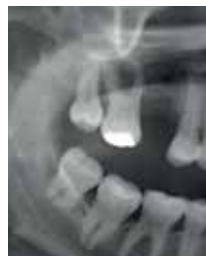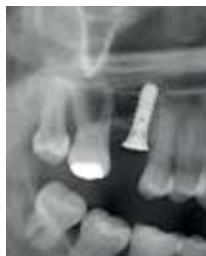could no longer be retained and was removed (Fig. 2). Following detailed consultation, the patient opted for a new implant in region 16. In order to clarify possible sinusitis, a DVT was created using Galileos – which had not been available to the implantologist at the time of the first implantation. This was done after the second implantation in region 16.

Positioning of the window directly on the implant (Fig. 3) showed no unusual results. When the window was moved toward cranial, however, the result was surprising: the nasal cavity was located where the maxillary sinus would normally be found (Fig. 4). When questioned, the patient explained that as a child she had had a bad fall and landed on her nose, and that she also has quite often breathed through her nose. It was obvious that this trauma was the most likely cause for the pronounced septum deviation which, given her externally perceived straight nose, could not be initially clinically determined. The displacement of the maxillary sinus was the reason for the problematic implant position.

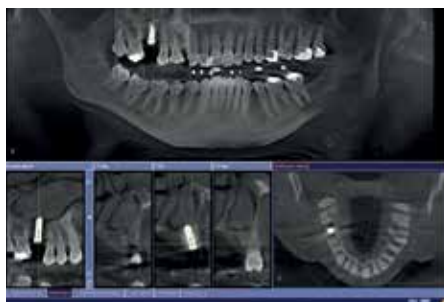
The implantologist who performed the procedure is not at fault; given the 2D imaging available, he could not possibly have recognized the atypical position of the maxillary sinus. This is only possible with DVT. This case confirms the essential nature of 3D diagnostics

in implantological rehabilitation: the most important diagnostic information is available at a glance. Excellent image quality and functionality also play a role here. The essential qualities of GALILEOS X-ray images are their high resolution and excellent contrast relative to the exposure required. A further plus is the fact that the hardware is, in many ways, simpler to operate than conventional panoramic units. In particular, it is much easier to position the patient.

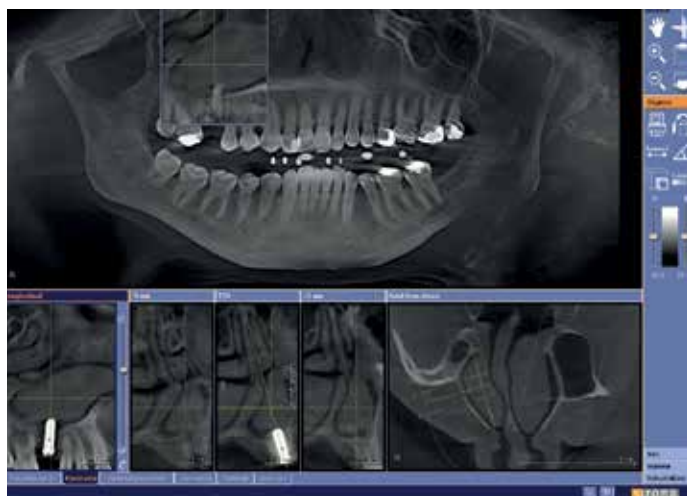📄 The complete case study in German was published in: Scheifele C, 3D-Röntgen nach Implantat-Komplikationen. Dental Magazin, 5/2007.



1 Postoperative half-view exposure with normal implant position. **2** [right] Half-view panoramic x-ray following explantation.



3 Both in the panoramic exposure and in the three transversal slices, a soft-tissue density opacity could be diagnosed which appeared to be delimited by air.

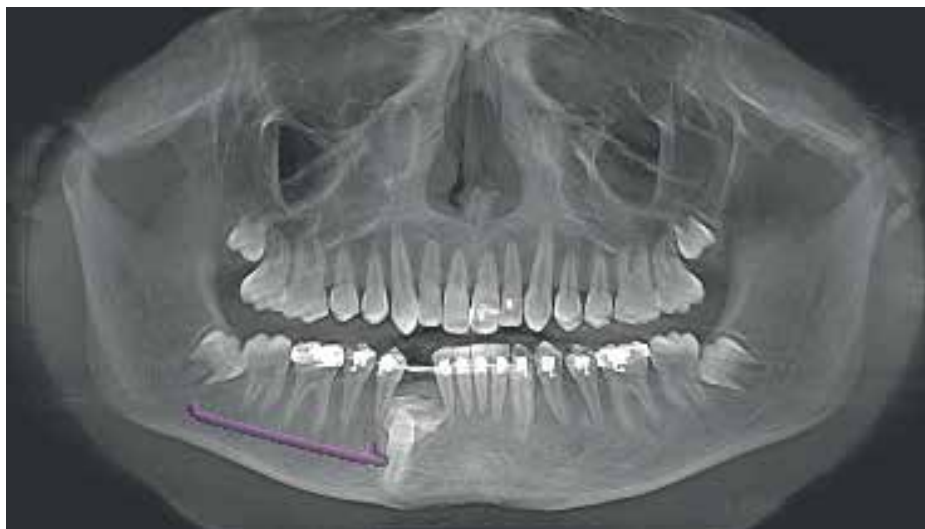

4 Upon moving the examination window cranially, it became evident that the implant position was partially located in the right nasal cavity.

3D IMAGE IDENTIFIES ODONTOMA

AUTHOR Dr. Fred Bergmann, Viernheim (Germany)

A male patient presents a displaced tooth in region 43. The 3D image identified an odontoma, enabling treatment to be performed exactly as planned, without surprises.

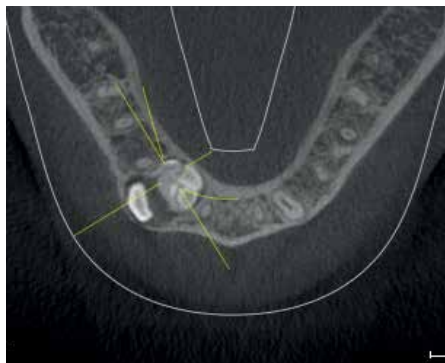

1 Initial situation in the panoramic X-ray view. The mandibular canal can be marked in color on the DVT image.

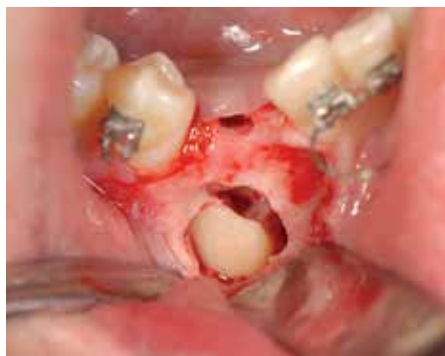The main advantage of the DVT technique is the highly informative nature of the X-ray volume. It becomes possible to reach a comprehensive diagnosis, which makes both therapy planning and treatment easier for practitioners. Take, for example, the case of a young male patient with a displaced canine tooth (region 43).

Thanks to the 3D image, we discovered a complex odontoma in region 43 (Fig. 1). With this knowledge, we were able to tailor treatment precisely to these findings. The axial view (Fig. 2) clearly shows that the displaced tooth is positioned vestibularly while the odontoma is positioned lingually. This information was of central importance when planning the intervention. We were able to expose the tooth vestibularly, while the odontoma was removed from the lingual side. Exact pre-planning made the operation much simpler for the practitioner since there was no risk of surprises during the intervention. And the operation was also less traumatic for the patient. Displaced tooth 43 was then exposed vestibularly and inserted orthodontically. The odontoma was also removed lingually.

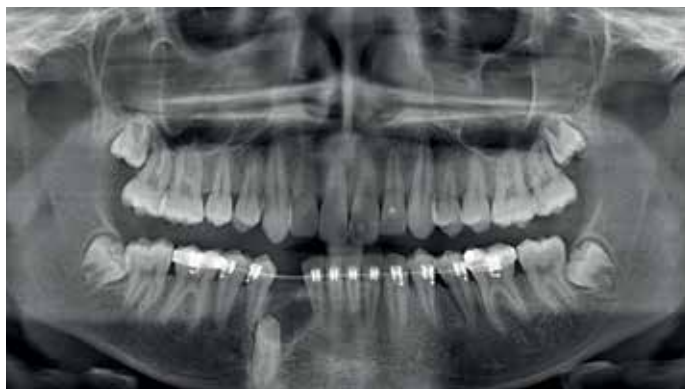👉 The complete case study in German was published in:
Bergmann F; 3D-Aufnahme deckt Odontom auf. Oralchirurgie
Journal, 4/2011.



2 It is possible to determine the exact positioning of the odontoma and the displaced tooth by evaluating the axial layer.



3 Exposed tooth 43. The odontoma is removed from lingual.



4 Following successful intervention: the odontoma has been removed. Exposed, displaced tooth 43 is integrated orthodontically.

EXACT DETERMINATION OF THE POSITION: BASIS FOR MINIMALLY INVASIVE ORTHODONTIC EXPOSURE

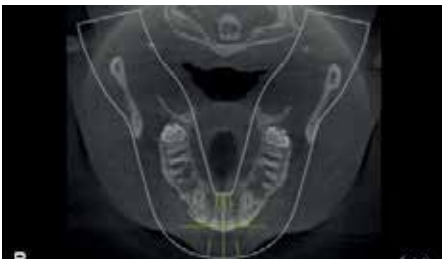AUTHOR Dr. Fred Bergmann, Viernheim (Germany)

One of the most frequent cases of tooth retention is the palatal or vestibular displacement of the remaining canine teeth in the upper jaw. Spontaneous penetration does not always occur in such cases when the deciduous teeth are removed. In order to render the intervention as a traumatic as possible, the position of the canine teeth should be determined precisely by means of digital volume tomography (DVT).

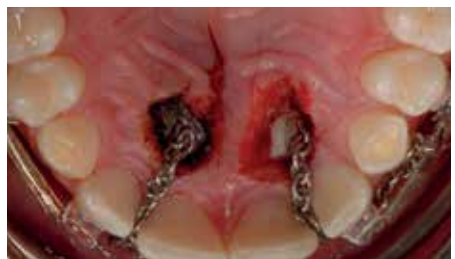In the case of a 17-year-old male patient, the upper canine teeth were retained palatally. The dentition had already been treated orthodontically, but space for the missing canine teeth had not yet been created. A DVT was produced to determine the correct surgical method and to establish the position of the canine teeth crowns as accurately as possible. The 3D image showed that the canine teeth crowns were located between the first and second incisors and that their labial surfaces were located on the palatal side. This allowed all risks to be weighed in advance,

enabling the intervention to be performed as atraumatically as possible for the patient. Since the teeth were still covered by bone, the crowns were exposed by local osteotomy. The laser provided valuable assistance here. On the one hand, it reduced bleeding to a minimum – a key prerequisite for adhering the brackets. On the other hand, as a result of the laser surgery, the patient had fewer post-operative complaints.

📖 The complete case study in German was published in:
Bergmann F; Exakte Lageermittlung: Basis für minimalinvasive Kieferorthopädie. ZWR 12/2011.



1 The position of the vestibular tooth surface is determined in the axial view.



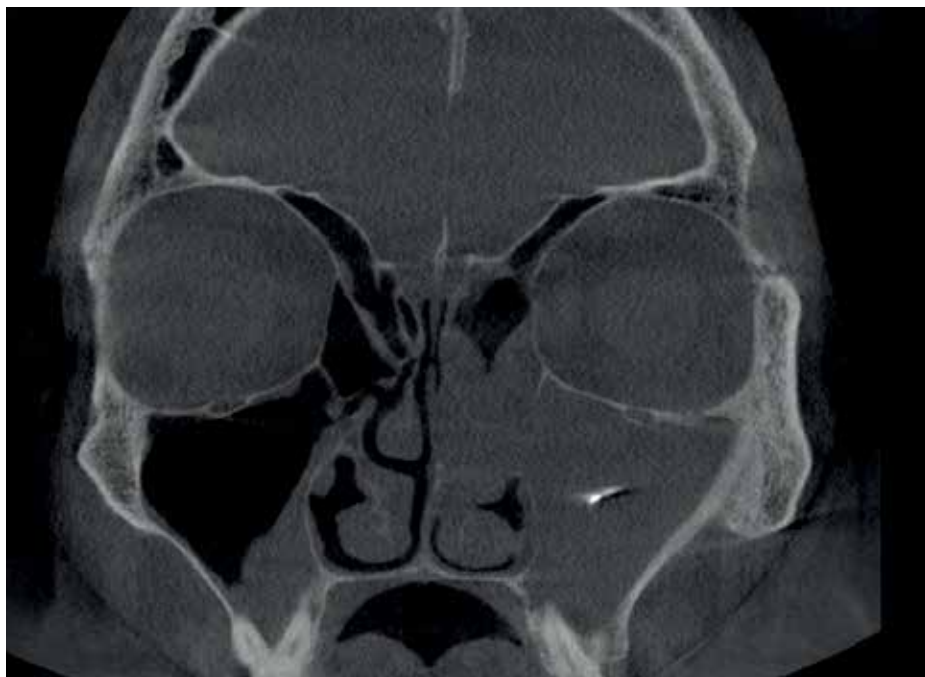2 State after adhesive fixation of brackets and retainers.

DVT FACILITATES THE DIAGNOSIS OF CHRONIC RHINORRHEA AND POSTNASAL SECRETION

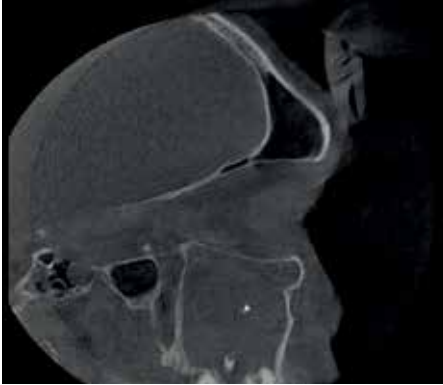
AUTHOR Dr. Marco Capelli, Codogno (Italy)

Additionally, in the area of ENT, 3D imaging ensures more precise diagnostics, safer planning and more effective treatment in comparison to other imaging systems. This improves communication with patients and increases overall satisfaction.

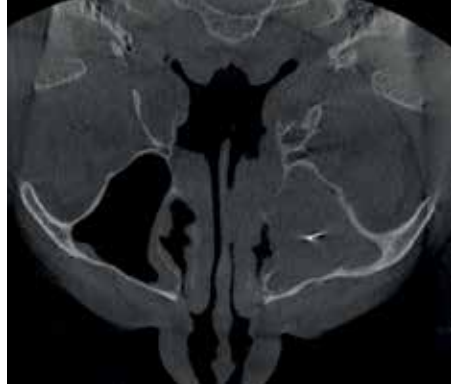
An increasing number of mycoses have been diagnosed in the nasal and sinus areas over the past years. These parasitic infections are frequently caused by types of *Aspergillus*. In some cases, an aspergilloma (fungus ball) forms in the maxillary sinus, a common form



1 Coronal view of the affected maxillary sinus with hyperintense material due to a mycotic build-up.



2 Sagittal view of the maxillary sinus.



3 Axial view of the maxillary sinus.

of chronic rhinosinusitis. The typical symptoms of acute rhinosinusitis cannot be determined until later. In many cases, this occurs together with bacterial superinfections – as in the case of one patient who had been suffering from purulent rhinorrhea, postnasal drip syndrome and cacosmia for a number of months. He had already been treated with antibiotics, steroids and an aerosol. However, these treatments had not resulted in improvement.

The patient was examined endoscopically at our practice, enabling us to diagnose congestion of the osteomeatal complex and a

translucent polypoid formation in the central nasal passage. Using GALILEOS, we performed a DVT of the facial skull without using a contrast agent. We discovered an area with strong hyperintensity in the left maxillary sinus. The accumulation of material with a structure with the density of bone or metal led us to believe that this was an aspergilloma. On the basis of these findings, the focus of infection could be removed during a rhinosurgical intervention. Thanks to DVT, we were provided with valuable information which was not available endoscopically. As a result, we were able to plan and execute treatment successfully.

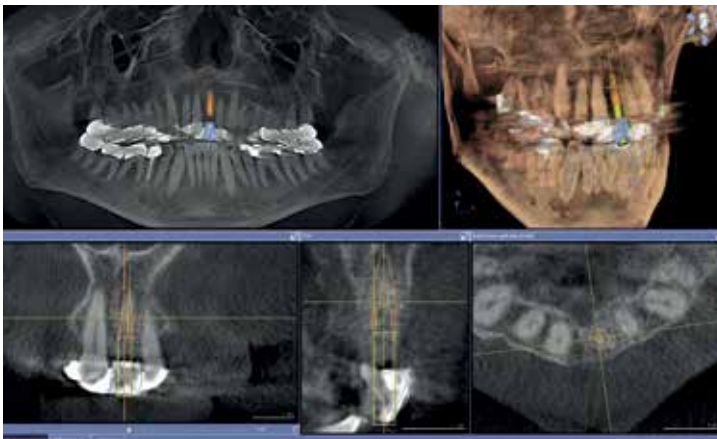IMPLANT PLANNING INTEGRATES CAD/CAM AND DVT

AUTHOR Dr. Viktor Karapetian, Cologne (Germany)
PD Dr. Dr. Lutz Ritter, PD Dr. Dr. Martin Scheer, Prof. Dr. Dr. Joachim E. Zöller

The combination of various technologies in the world of dentistry opens up new treatment approaches. Thanks to integrated implantology, practitioners can now optimally plan implantation and, to a large extent, avoid risk even before the actual intervention.

With integrated implantology, dentists specializing in implantology can superimpose the 3D X-ray data from the GALILEOS system onto the restoration proposal from CEREC to harmonize surgical and prosthetic planning. The combination of both technologies offers practitioners significant advantages. They acquire a precise image of the jaw and tooth situation prior to the actual intervention, are able to ensure the presence of sufficient bone material at the required points, and can select the right implant size.

Using GALILEOS, we produced a 3D X-ray image of a 59-year-old male patient with anterior tooth trauma on teeth 21 and 11. We thereby determined that tooth 21 had to be removed due to a transverse fracture of the tooth root. Using the CEREC CAD/CAM restoration system, we created a restoration proposal and imported this into the DVT data with the GALILEOS Implant planning software. The practitioner marked corresponding points in the CAD/CAM data and in the 3D X-ray image



1 Integrated implant planning with GALILEOS and CEREC allows practitioners to create an ideal basis for treatment with just a few clicks.

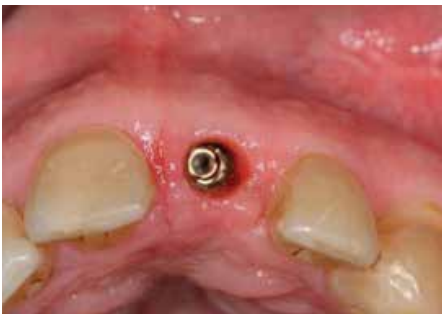to allow the software to superimpose both data sets precisely.

During planning, it became evident that the lingual bone wall was not thick enough for an implantation, so we performed surgical socket preservation with granulate following removal of tooth 21. Tooth 11 was also restored with an acrylic filling and we splinted the entire anterior region in order to stabilize the teeth in position. We exposed the implant after three months and produced the final restoration with CEREC as follows: We adapted the restoration proposal - which we constructed virtually to the requirements of this case - and, using the CEREC MC XL milling machine, milled the restoration from multicolored layered feldspathic ceramic. The implant crown was customized and finished with final firing and cemented onto the abutment.

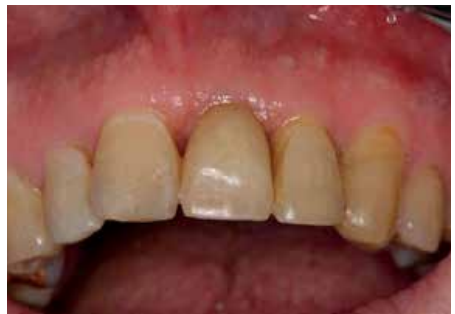Integrated implantology provides practitioners with added value: it simplifies diagnostics and increases planning certainty.

Virtual planning of the entire treatment process enables users to avoid potential complications. The practitioner's treatment proposal is also more transparent and easier for patients to understand.

➤ The complete case study in German was published in: Karapetian V, et al., Implantatplanung integriert CAD/CAM und DVT. Oralchirurgie Journal 2/2012.



2 Exposure three months after osseointegration: the gingiva has healed well.



3 Final clinical result: restored teeth 11 and 21 dovetail perfectly with the overall look.

SAFETY FIRST FOR IMPLANTOLOGY

AUTHOR Jochen Kusch, Executive Vice President Marketing and Sales of SICAT, Bonn (Germany)

Many implantologists would like to see an increase in treatment safety. The use of digital technologies is all-important here, since the combination of DVT and CAD/CAM data facilitates the production of drill templates.

The use of 3D X-ray images reduces the risk of unintentionally damaging anatomical structures and allows the bone situation to be assessed even before actual intervention. Using 3D X-ray and CAD data plus implant planning software, dentists can precisely plan where and at what angle the implant must be positioned and whether sufficient bone substance is available.

The virtual plan can be used to produce drill templates with one of three options: CLASSICGUIDE, OPTIGUIDE and CEREC Guide.

1. CLASSICGUIDE method

First, the dentist takes an impression using the conventional method. The dental technician waxes up the proposed restoration on the model and produces a deep-drawn tray into which the prosthetic proposal containing barium sulphate is integrated. This is fixed to an X-ray template. Alternatively, with more simple cases, the bite registration can be applied directly to the X-ray template. The patient wears this X-ray template during the DVT imaging process. The reference balls on

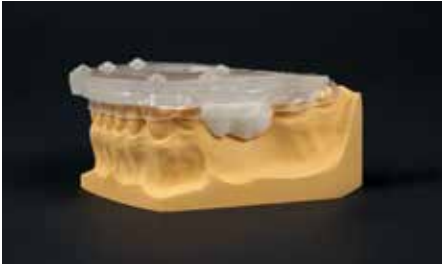the bite plate enable perfect positioning later during preparation of the drilling templates. After planning the implant, the dentist sends the 3D X-ray data, the plan and the X-ray template to SICAT.

This workflow functions reliably both for edentulous jaws and jaws fully restored with metal crowns. SICAT analyzes the feasibility of each drilling template as a special service. Manufacturing accuracy is measured at the apical end of the implant and guaranteed to be under 0.5 mm.

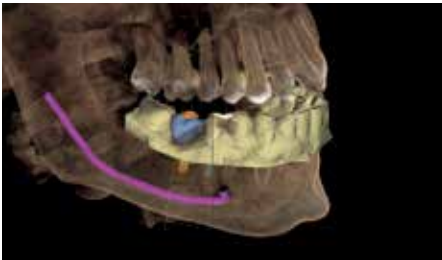
2. OPTIGUIDE method

When the implantologist uses CEREC, he or she can greatly simplify the process. The dentist captures the visual tooth situation with the CEREC camera and constructs the prosthetic recommendation using CEREC restoration software. He or she imports the CAD data into the implant planning software and merges it with the 3D X-ray data of a Sirona DVT. This process virtually matches the surgical and prosthetic planning. Next, he or she transfers the digital planning data simply by uploading them to the SICAT surgical fabrication template.

This simplification of the workflow means considerable time savings for the dentist, since he can dispense with a radiographic guide.



1 X-ray template with proposed restoration made of barium sulfate.



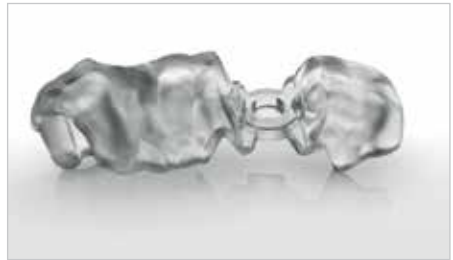3 The virtual model with the implant (shown in orange) and implant crown (blue) are integrated into the X-ray data. There is sufficient distance to the mandibular canal (colored purple).

3. CEREC Guide method

CEREC users will be able to produce their own drilling templates (CEREC Guide 2) with a CEREC MC XL production unit. The impression formed by CEREC, the soft tissue information and the pre-planned prosthetics are merged to the GALILEOS system 3D data set. GALILEOS Implant does the planning. Next, the planning results are transmitted back to CEREC and milled from a PMMA plastic block. Neither a physical model nor a second X-ray scan with reference markers is required.



2 SICAT OPTIGUIDE drilling templates with surgical sleeves in different sizes.



4 With the new CEREC 4.4 software, one can use CEREC Guide 2 to produce the drilling template for guided surgery quickly, easily and very inexpensively – right in the dental practice.

Conclusion

Each of the three methods leads to one goal: increased reliability through guided implantology. Depending on equipment and preferences, the practitioner decides on either the premium service of the drill template manufacturer with safety controls, or the fast and comfortable chairside procedure.

Original German-language version of the article can be found in: Kusch J, Safety first in der Implantologie. Dentale Implantologie 11/2011.

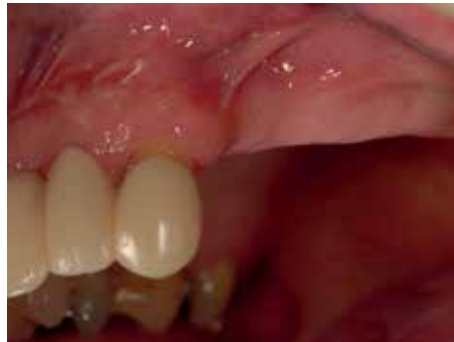3D DIAGNOSTICS FOR A COMPUTER-AIDED IMPLANT PLAN WITH EXTERNAL SINUS LIFT

AUTHOR Dr. Fred Bergmann, Viernheim (Germany)

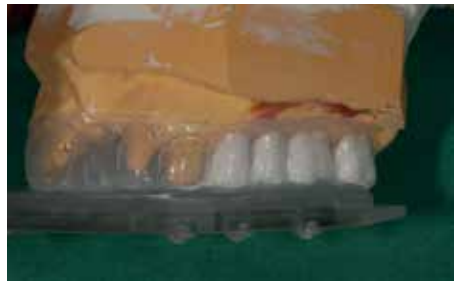In edentulous regions of the jaw, bone material can recede rapidly due to lack of use. If an implant restoration is planned, the remaining bone structure must first be measured. Digital volume tomography (DVT) is an invaluable aid for such an assessment.

The advantages of DVT images include hard tissue structures being displayed with a high image quality, and patients being exposed to a comparatively low dose of radiation. This is especially important when planning implant treatment that involves insufficient supportive bone material, resulting in the dentist having to decide on a suitable augmentation method. For larger procedures such as an external sinus lift, precise findings from 3D X-ray images contribute considerably to reducing surgical trauma.

In a 49-year-old patient, the missing teeth in region 24 to 27 were to be replaced with a fixed prosthesis on four implants. The computer-aided planning of the implants in 3D volume showed that the maxillary bone required augmentation. Due to the large size of the implant treatment, only an external sinus lift was possible for bone augmentation. In this method, the insertion of bone and bone sub-

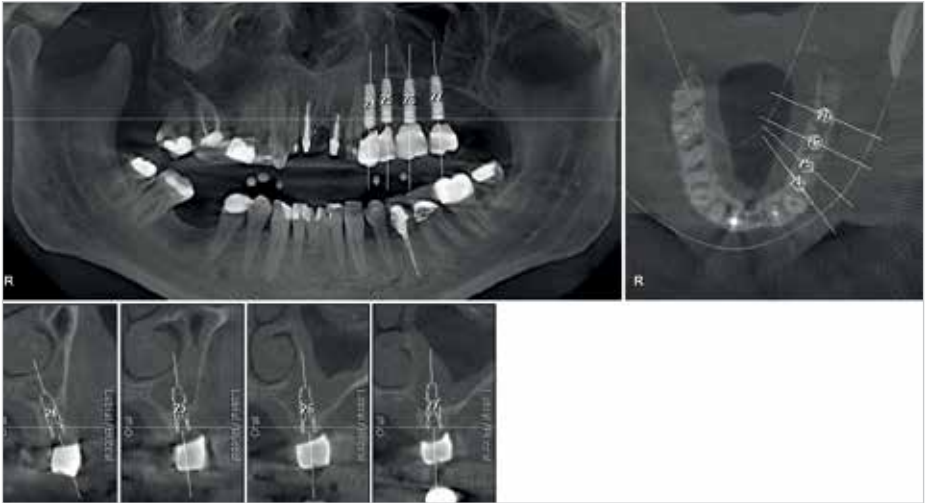


1 Initial clinical situation of region 24 to 27.

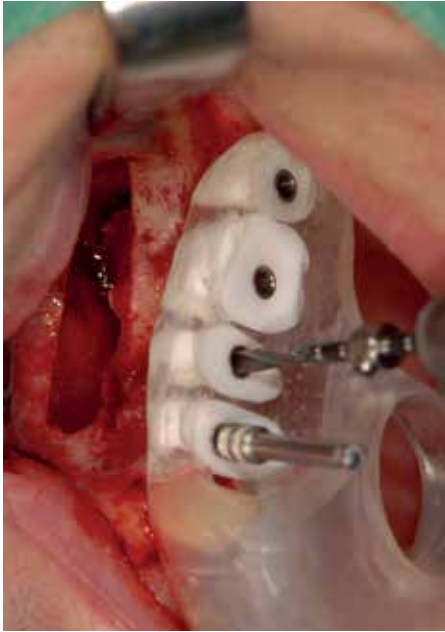


2 X-ray template with the planned prosthesis.

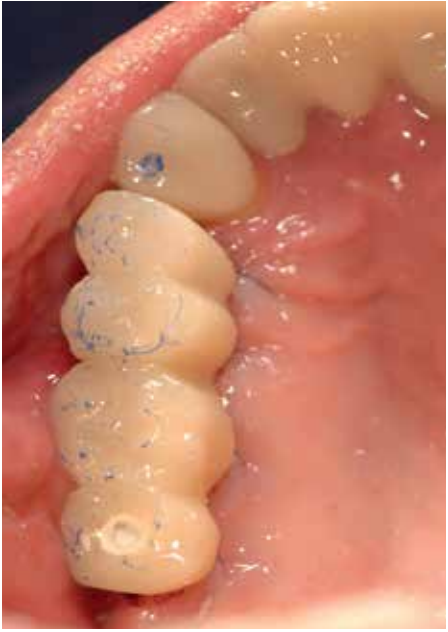stitute material augmented the jaw enough to provide adequate support for the implants. The integrated and guided implantation gave the surgeon a high degree of security.



3 The reporter function allows for a clear overview of the planned treatment.



4 Precise drilling using the SICAT guide on a jaw that was previously augmented with bone substitute material.



5 The final restoration.

BENEFITS OF INTEGRATED IMPLANT IN AT RISK PATIENTS

AUTHOR Dr. Martin Butz, Munich (Germany)

Forward planning for implant surgery is no longer state of the art. Advanced practitioners start with the desired results when planning for the operation of the desired prosthetic treatment. Today, they can take advantage of innovative methods such as integrated implants and drilling templates – methods which have proven themselves especially valuable with high-risk patients.

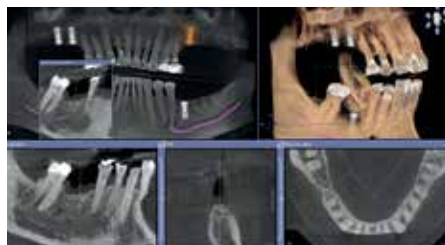Patient was a 63-year-old female who was a heavy smoker and very dissatisfied with her bite situation. She had seven missing teeth. We first made a DVT impression in order to in advance assess the conditions for successful implantation. It showed sufficient bone material for the required implants in the vertical and horizontal directions.

Due to the anatomical conditions and the free end situation, a situation model was created in the practice laboratory with corresponding wax-ups of the intended crowns, and was then digitized using a CEREC Bluecam. Next, the digital data from the GALILEOS Implant planning software was imported using the OPEN GALILEOS interface. The software displayed the virtual crowns at the appropriate point in the 3D X-ray image. This facilitated surgical planning according to the desired

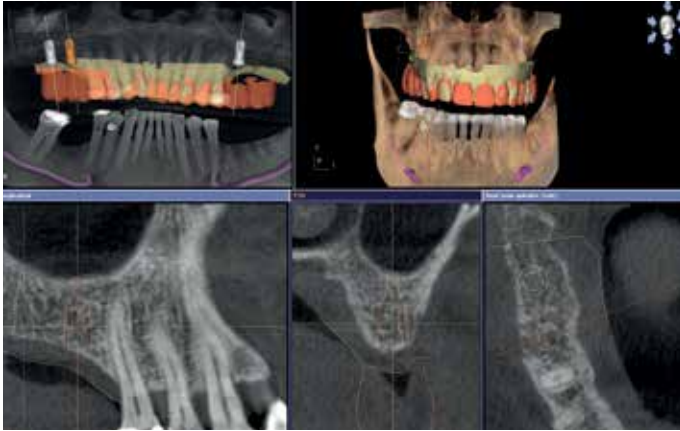prosthetic restoration. Based on this virtual, integrated implant planning, we ordered two drill guides – one each for the upper and lower jaw – from SICAT.

Implants 16, 17, 26, 36 and 46 were inserted in accordance with the integrated implant plan. After a healing phase of four months, we exposed the implants and designed the emergence profile. Next, the implants were molded with Impregum® using individual plastic partial trays, and the prosthetic restoration was made in the dental laboratory. The patient is now symptom-free and very satisfied with the new treatment.

👉 The complete case study in German was published in: Butz M, Vorteile der integrierten Implantologie bei Risikopatienten. Zahnarzt & Praxis, 5/2013.



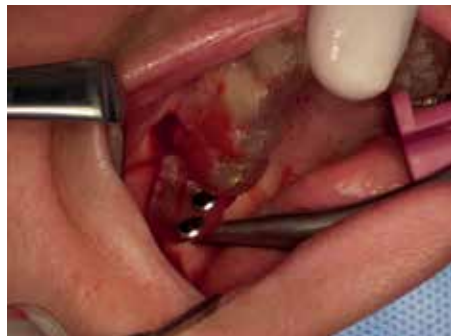1 Integrated implant planning in the X-ray software.



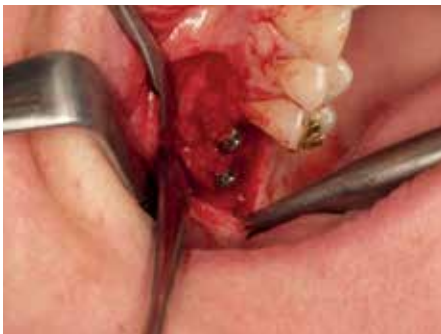2 DVT and prosthetic planning are merged in the x-ray software.



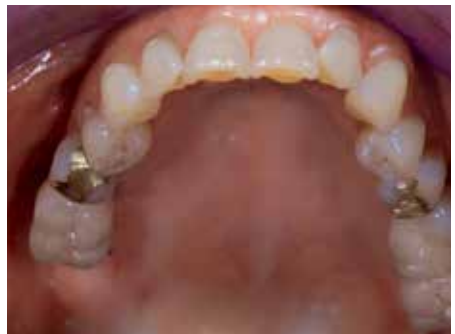3 The drilling templates made by SICAT specified the position and di-rection during the procedure.



4 The drilling template is firmly seated in the patient's mouth.



5 The implant was stabilized after insertion through augmentation with autogenous bone.



6 The prosthetic restoration of teeth 16, 17 and 26.

CMD DIAGNOSIS AND THERAPY IN ONE APPOINTMENT

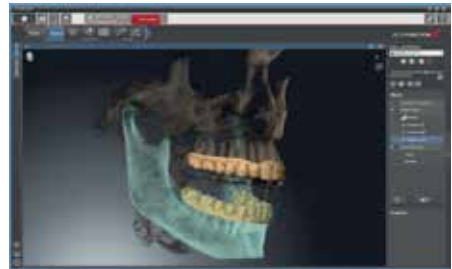
AUTHOR Jochen Kusch, Executive Vice President Marketing and Sales of SICAT, Bonn (Germany)

In order to diagnose and treat craniomandibular dysfunctions (CMD), SICAT Function uses the DVT (GALILEOS) to record 3D image data, which is then combined with movement measurements (SICAT, JMT+) and digital surface data (CEREC). As a result, an anatomically precise, actual dynamic patient situation is presented that can be comprehensively analyzed for the first time. Changes in the joint gaps when taking defined mandibular positions or in the course of mandibular movement can be displayed directly as measurements.

During DVT recording and at the beginning of a JMT measurement, the patient bears a reference tray with radiopaque markers, the SICAT FusionBite. With SICAT JMT+, the jaw's real positions and movements are recorded with all six degrees of freedom. The movement paths can be visualized at any specific point on the mandible. In this way, the spatial relationship between the condyle and fossa in motion can be illustrated individually for the first time. Dynamic occlusion can also be tracked for each jaw position using the CEREC optical impression function. To accomplish this, the optical impressions acquired during the intraoral scanning procedure can be metrically superimposed on the DVT data with perfect accuracy. After diagnosis and analysis of the data at hand, the practitioner can decide

whether or not to order a machine-made OPTIMOTION therapy track from SICAT. SICAT OPTIMOTION is based on the Michigan Principles and can be produced according to the practitioner's preferences.

➤ Original German-language version of the article can be found in: Kusch J; SICAT Function. Kieferorthopädie Nachrichten, Kompendium 2014.



1 Dynamic occlusion with SICAT Function using the merged surface data.



2 Using the SICAT OPTIMOTION therapy track the dentist is able to treat temporomandibular joint problems.

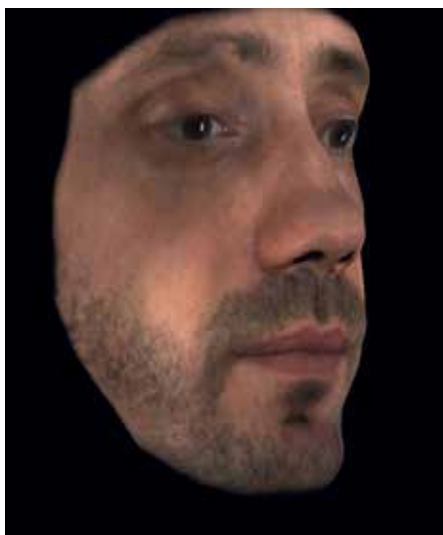INTEGRATED FACESCAN SUPPORTS DIAGNOSIS AND SURGICAL PLANNING

AUTHOR PD Dr. med. Dr. med. dent. Lutz Ritter, Hennef (Germany)

Face scanners may help orthodontists and oral and maxillofacial surgeons in treatment planning and patient communication. The prerequisite for such use of technology: the surface data of the patient's face must be precisely superimposed on the 3D X-ray data.

In our practice, we predominantly use the GALILEOS DVT device with an integrated Facescan for patients with striking extra oral findings such as facial asymmetry. Facescan delivers an exact 3D reproduction of the surface, facilitating the analysis and evaluation of the facial proportions, including the nose, lips and chin configuration. On the basis of the 3D illustration of the face, we create the clinical findings and follow up with an orthodontic or orthognathic jaw surgery treatment plan.

In the present case, after bimaxillary osteotomy and surgical correction of the remnant chin, the supramental scarred inclusion disturbed the patient. A preoperative DVT Facescan clearly displayed the remaining metal and incomplete osseous regeneration with the resulting inclusion (Fig. 1). We recommended that the patient undergo metal removal and bony formation of hard and soft tissue structures to reduce the supramental deficit.

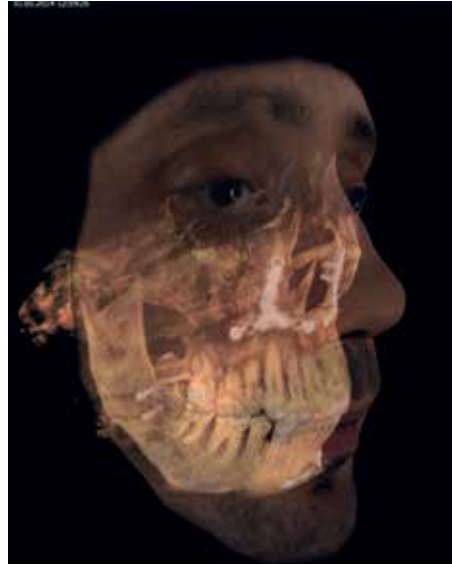

1 Initial findings with supramental scarring after bimaxillary osteotomy.

The use of the GALILEOS integrated facial scanner offered a number of advantages in the treatment. On the one hand, the practitioner was able to use the facial scans in treatment planning, implementation and

documentation. In addition, the 3D presentation provided excellent orientation shortly before and during the surgery. The image of the patient's face could also be used to supplement the documentation of the treatment course and in before-and-after comparisons of the clinical and aesthetic situations. It also helped the patient to understand the planned treatment. No additional radiation dose is applied and there is no increase in the time required for the system to rotate.

The GALILEOS system with integrated Facescan is highly precise due to the surface and the 3D X-ray data being recorded simultaneously in the same coordinate system. As well, the computer can correctly classify them geometrically. The subsequent combination of face scans with separately created radiographs can not reach this level of precision. Since the images are calculated from the scanned 3D data, there is no distortion.



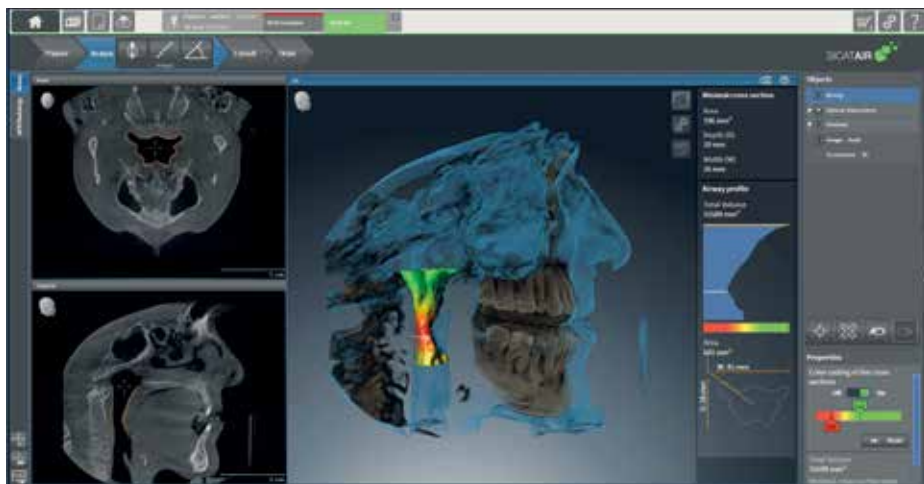
2 Preoperative situation with superimposed X-ray/surface data.



3 Condition after scar resolution and augmentation of the supramental fold.

TODAY'S INTEGRATED SOLUTIONS GIVE US A TASTE OF TOMORROW'S INNOVATIVE THERAPIES

AUTHOR Mark Bucher, Product manager 3D imaging, Bensheim (Germany)



1 Dentists analyze patient respiratory tracts and can order a protrusion prosthesis for treatment of obstructive sleep apnea.

The future of our health care system depends on whether or not we are able to make treatments efficient enough so that they are able to overcome the impact of aging and increasingly higher standards. More and more innovative treatment approaches have emerged through the integration of proven digital solutions in recent years. With their efficient workflows, they demonstrate today how dentistry will be managed in the future.

Digitization is now the basis for nearly all technological progress. The increasing integration of various digital technologies is becoming an increasingly important part of innovation. For example, Sirona systems aren't only standalone solutions, standalone solutions, but instead combine digital data to enable pioneering therapeutic concepts and efficient workflows in the areas of implantology, endodontics, orthodontics,

functional diagnostics and prosthetics. Digitization simplifies and accelerates many process steps, and system integration optimizes entire treatment processes. This includes networking many digital systems with one another, interconnected to patient management and controlled centrally.

CAD/CAM and digital X-ray technology have evolved over the past decades to become key technologies in dentistry. DVTs are now an integral part of many treatments, as shown by the case studies in this brochure. And we are constantly developing new therapy concepts that go beyond these applications.

Example, SICAT Air: For the first time, using this 3D software, we will present to the professional community at IDS 2015 the ability of dentists to analyze the upper airways of patients with obstructive apnea. Thanks to digital technology, we are now able to implement a customized therapy track in just two sessions. In addition, a 3D X-ray scan will

provide anatomical information about the respiratory tract and jaw joints in the protruded position. These data provide dentists with information about whether the therapy is working without having an adverse affect on the jaw joints. In the next step, the dentist records the digital surface data of both jaws using CEREC and merges this data with the DVT data using the SICAT Air software. Next, users can then transfer the data from the software to SICAT and order the mandibular protrusion appliance (SICAT OPTISLEEP).

The increasing interconnection of different systems is enabling efficient, reliable planning and the implementation of minimally invasive treatments. With our team of more than 300 scientists and engineers worldwide – who work primarily in our Bensheimer Innovation Center – and with our unique system expertise in the areas of CAD/CAM and imaging systems, treatment units, instruments and hygiene devices, we will continue pursuing these goals in the coming years.

LEGAL NOTICE

Publisher

Sirona Dental GmbH
Sirona Strasse 1
A-5071 Wals/Salzburg (Austria)
E-Mail: contact@sirona.com
Telephone: +43(0)662 2450-0
Fax: +43(0)662 2450-510
www.sirona.com

Responsible under german press law

Vincent Kummer, Marion Weixlberger,
Sirona Dental GmbH in Wals/Salzburg
(Austria)

Editorial and design

ergo Unternehmenskommunikation
GmbH & Co. KG
Venloer Straße 241 – 245
D-50823 Köln
www.ergo-komm.de

Special thanks also to:

Dr. Fred Bergmann, Dr. Martin Butz, Dr.
Marco Capelli, Dr. Gerd Frahsek,
Dr. Viktor Karapetian, Jochen Kusch,
PD Dr. Dr. Lutz Ritter, Dr. Christian
Scheifele

Printing

Offset 5020 Druckerei & Verlag
Ges.m.b.H.
Bayernstraße 27
A-5072 Siezenheim
Telephone: +43 (0)6628 570 70

We reserve the right to make technical modifications, typographical errors and mistakes.

SICATFUNCTION



TRACK REAL MOTION IN MOTION

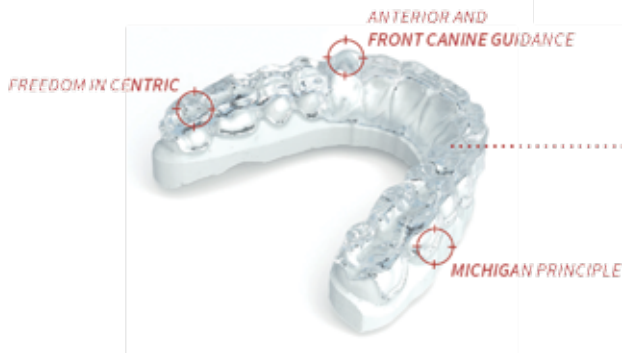
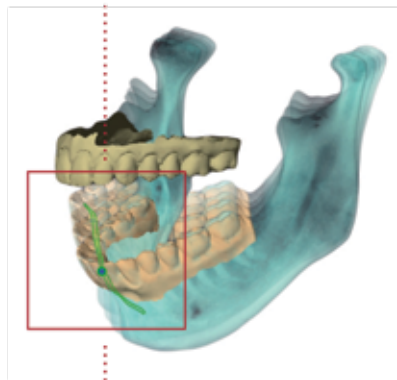
REAL 3D JAW MOTION FOR THE FIRST TIME!

SICAT Function gives dentists the information necessary for the precise diagnosis and advanced therapy of temporomandibular joint dysfunctions. Precise data from a 3D X-ray system, the SICAT JMT⁺ and optical impressions are merged in SICAT Function:

- 3D visualization of the jaw in motion
- Real traces of movement at any specific point of the mandible
- Relation between condyle and fossa in movement
- Now available: SICAT OPTIMATION, the fully digital therapeutic appliance

Your new secret of success – diagnosis, planning and consultation with the patient in one chairside session!

WWW.SICAT.COM



SICAT.

a **sirona** company